

# Percutaneous Mitral Annular Reduction Provides Continued Benefit in an Ovine Model of Dilated Cardiomyopathy

Melissa J. Byrne, BSc, BApSc; David M. Kaye, MB, BS, PhD; Mark Mathis, BSME;  
David G. Reuter, MD, BSME; Clif A. Alferness, BEE; John M. Power, BVSc, PhD

**Background**—Functional mitral valve regurgitation plays a key role in the symptomatic severity and progression of heart failure. In an ovine model of dilated cardiomyopathy, we examined the chronic functional consequences of mitral regurgitation reduction using a recently developed novel percutaneous mitral annular reduction (PMAR) device.

**Methods and Results**—Fourteen adult sheep were paced right ventricularly at 180 to 190 bpm for 5 weeks, leading to the development of moderate mitral valve regurgitation. After echocardiographic, hemodynamic, and neurohormonal analysis, 9 animals underwent PMAR. All animals were subsequently paced for another 28 days, and a final echocardiographic and hemodynamic study was conducted. Animals that had undergone PMAR showed significantly increased negative and positive dp/dt, whereas pulmonary capillary wedge pressure and mitral valve regurgitation were significantly reduced compared with those at device implant despite continued pacing. In conjunction, significant improvements in plasma norepinephrine and brain natriuretic peptide were apparent.

**Conclusions**—The application of PMAR in animals with pacing-induced dilated cardiomyopathy and functional mitral valve regurgitation resulted in continued improvements in hemodynamic and neurohormonal parameters. (*Circulation*. 2004;110:3088-3092.)

**Key Words:** mitral valve ■ regurgitation ■ catheterization ■ cardiology ■ cardiomyopathy

The development of functional mitral regurgitation has been demonstrated to be associated with a poorer prognosis and greater symptomatic impairment in patients with heart failure (HF).<sup>1,2</sup> Mitral regurgitation results in left ventricular (LV) volume overload and increased diastolic wall stress, which leads to further LV remodeling and an energetically unfavorable environment.<sup>3</sup> The presence of mitral regurgitation is associated with the further activation of neurohormonal- and cytokine-based systems that are typical of HF.<sup>4–7</sup> We have previously shown that activation of the sympathetic nervous system may in part be the result of elevated left atrial (LA) and pulmonary arterial pressures,<sup>8</sup> providing a mechanistic link for the association between mitral regurgitation and neurohormonal activation in HF.

The mechanism for the development of functional mitral regurgitation in dilated cardiomyopathy is the failure of mitral leaflet coaptation. This relates to structural changes that are associated with ventricular remodeling, including LV and mitral annulus dilatation,<sup>9,10</sup> in association with changes in the geometry of the chordae tendineae.<sup>11</sup> Of relevance to this study, it has been shown that annular dilatation is the primary cause of mitral regurgitation development<sup>10</sup> in the ovine pacing model of HF.

Although angiotensin-converting enzyme inhibitors and  $\beta$ -adrenoceptor antagonists<sup>12,13</sup> have been shown to have

some favorable effects on mitral regurgitation, most patients who develop mitral regurgitation are already receiving anti-failure therapy. In conjunction, surgical approaches have also been applied for the management of HF-associated mitral regurgitation.

Recently, we have shown that acute application of a novel percutaneous mitral annular reduction (PMAR) device in an experimental model of dilated cardiomyopathy<sup>14</sup> resulted in elimination or minimization of mitral regurgitation.<sup>15</sup> This acute reduction of mitral regurgitation was associated with favorable effects on cardiac output and wedge pressure. In the present study we sought to extend our observations and to specifically test the hypothesis that sustained reduction of PMAR affords continued favorable hemodynamic and neurohormonal effects.

## Methods

The investigation conforms with the *Guide for the Care and Use of Laboratory Animals* published by the US National Institutes of Health (NIH Publication No. 82-23, revised 1996).

## Initial Surgical Preparation of Animals

Fourteen adult crossbred sheep (weight, 45 to 55 kg) were anesthetized with 2 mg/kg propofol and maintained on isoflurane and oxygen. A bipolar screw fixation ventricular pacing lead was placed

Received January 16, 2004; de novo received March 25, 2004; revision received June 15, 2004; accepted June 21, 2004.

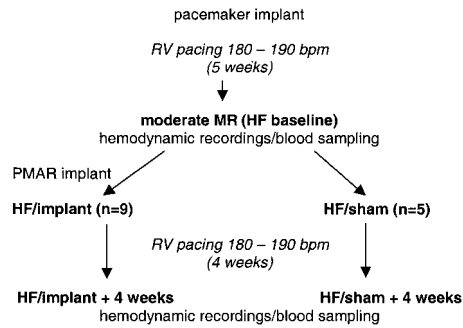
From the Department of Applied Cardiovascular Research (M.J.B., J.M.P.) and Wynn Department of Metabolic Cardiology (D.M.K.), Baker Heart Research Institute, Melbourne, Victoria, Australia; and Cardiac Dimensions Inc, Kirkland, Wash (M.M., D.G.R., C.A.A.).

Correspondence to John M. Power, BVSc, PhD, Department of Applied Cardiovascular Research, Baker Heart Research Institute, PO Box 6492, St Kilda Rd Central, Melbourne, Victoria 8008, Australia. E-mail john.power@baker.edu.au

© 2004 American Heart Association, Inc.

*Circulation* is available at <http://www.circulationaha.org>

DOI: 10.1161/01.CIR.0000146904.13677.E4



**Figure 1.** Schematic diagram of implant protocol indicating timing and nomenclature of procedures. MR indicates mitral regurgitation.

transvenously under fluoroscopic guidance in the apex of the right ventricle (RV). The proximal end of the lead was connected to pacemakers reprogrammed for high-rate pacing (Sigma, Medtronic) that were positioned subcutaneously in the lateral aspect of the neck. Oxytetracycline (5 mL), an antibiotic, and flunixin meglumine (1 mL), an analgesic, were administered subcutaneously prophylactically on the day of surgery. After 3 days of recovery, RV pacing was initiated at 180 to 190 bpm.

### Experimental Protocol

All animals underwent rapid RV pacing for 5 weeks to obtain moderate mitral regurgitation. As depicted in Figure 1, animals then underwent detailed hemodynamic and neurohormonal assessment. Subsequently, animals were randomized by lot to PMAR implant<sup>9</sup> or no implant.<sup>5</sup> All animals were then paced for an additional 4 weeks, followed by a final echocardiographic, hemodynamic, and neurohormonal evaluation.

### Echocardiography

All animals underwent right-sided transthoracic echocardiography while conscious (Cypress, Acuson) at the intervals indicated in Figure 1. LA and LV dimensions and cross-sectional areas were determined by planimetry in a long-axis equivalent view. Mitral annular diameter is the septolateral measurement in the long-axis equivalent view. Given the nature of echocardiographic imaging in sheep, it was not possible to perform volumetric measurements, and therefore fractional area changes are reported. The degree of mitral valve regurgitation was assessed with the use of color Doppler to determine the mitral regurgitant jet area as a percentage of LA area (mitral regurgitation/LA%).

### Device Implantation and Hemodynamic Evaluation

The animals were anesthetized with 2 mg/kg propofol and maintained on a continuous infusion of ketamine 15 mg/kg per hour and propofol 30 mg/kg per hour. A Millar micromanometer catheter was positioned in the LV via a 5F introducer sheath located in the carotid artery. A 9F introducer sheath was positioned in the jugular vein to allow access of a 7F flow-directed thermodilution catheter (Swan-

Ganz, Baxter Edwards) to measure pulmonary arterial pressures and cardiac output (an average of 4).

In the 9 animals randomly allocated to implant, a 9F guide sheath was placed in the coronary sinus and along the great cardiac vein to the level of the anterior interventricular vein, under fluoroscopic guidance. PMAR was performed in the following manner. A percutaneous annuloplasty device (Cardiac Dimensions Inc), consisting of 2 anchors (proximal and distal) linked by nitinol wire, was advanced down the 9F guide sheath. The distal anchor was exposed and locked in position in the distal great cardiac vein, near the posterior interventricular vein. Tension was placed on the system to reduce the mitral annulus, and then the proximal anchor was deployed and locked in position in the approximate mid coronary sinus so that the anchor was contained within the coronary sinus. The aim was to produce a 20% to 25% reduction in the long-axis mitral annulus (septolateral) dimension. An initial judgment of this value was made by experienced appraisal (with device and rib edges used as landmarks) and confirmed, before the device was locked in position with the use of echocardiography.

### Neurohormonal Analysis

Arterial blood samples were collected after 5 weeks of pacing, at the time of hemodynamic evaluation and at 4 weeks of additional RV pacing after implant for the quantification of norepinephrine and brain natriuretic peptide (BNP) levels. The samples were collected into tubes containing reduced glutathione for norepinephrine analysis and containing EDTA for analysis of BNP. All samples were centrifuged and stored at  $-80^{\circ}$ . Plasma norepinephrine levels were determined with the use of high-performance liquid chromatography by a method previously described.<sup>16,17</sup> BNP concentrations were established with the use of radioimmunoassay techniques, as previously described.<sup>18,19</sup>

### Statistical Analysis

Data were analyzed with the use of a SigmaStat computer program (Jandel Scientific). Analysis of variance for repeated measures, followed by Bonferroni post hoc test, was used to compare changes between before the mitral valve reconfiguration and after 4 weeks of additional RV pacing and between implanted and nonimplanted controls at 4 weeks of additional pacing. Values are expressed as mean  $\pm$  SEM; a probability value  $<0.05$  was considered significant.

### Results

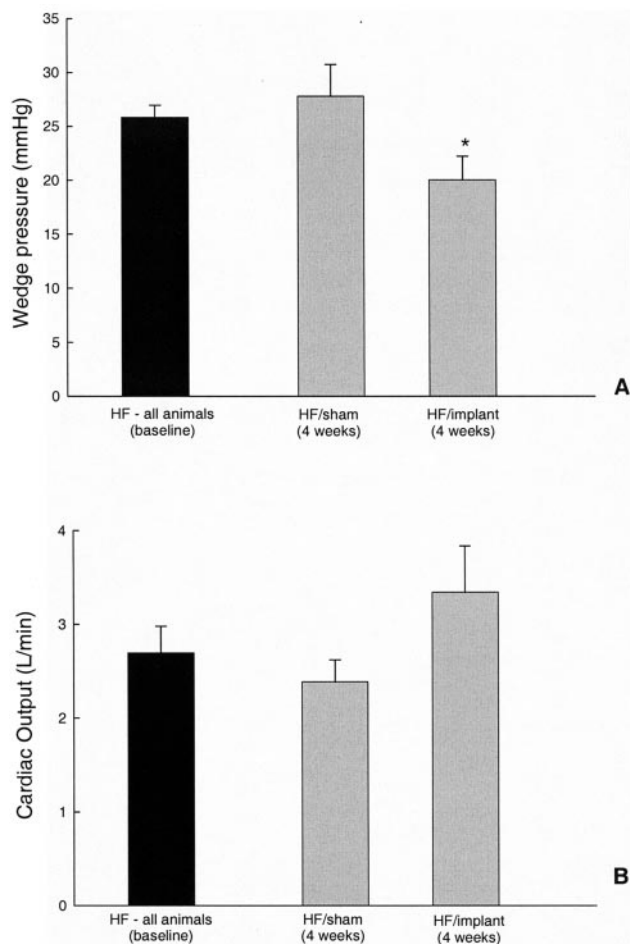
No deaths occurred in animals before the termination date. As shown in the Table, after 5 weeks of rapid RV pacing, all animals exhibited moderate mitral regurgitation (mitral regurgitation/LA%). Four weeks after implant with sustained pacing, there was an ongoing mitral annular reduction of  $23.70 \pm 1.45\%$ , which resulted in a significant ( $P < 0.05$ ) attenuation of mitral regurgitation compared with HF controls. There was no significant difference ( $P > 0.05$ ) in ejection fraction between implanted and nonimplanted animals at 4 weeks. LV area significantly increased after 4 weeks of additional pacing in both nonimplanted and implanted ani-

**Transthoracic Echocardiographic Data for Groups of HF/All Animals (Baseline), HF/Sham+4 Weeks, and HF/Implant+4 Weeks**

	MR/LA%	Ejection Fraction, %	Mitral Annulus, cm	% Reduction	LV Area, cm <sup>3</sup>	LA Area, cm <sup>3</sup>
HF/all animals (baseline)	27.84 $\pm$ 1.96	37.21 $\pm$ 3.18	4.04 $\pm$ 0.14	...	31.32 $\pm$ 1.16	22.03 $\pm$ 1.07
HF/sham +4 weeks	31.86 $\pm$ 3.64	36.20 $\pm$ 3.20	4.44 $\pm$ 0.13	...	38.64 $\pm$ 1.47*	29.63 $\pm$ 0.90*
HF/implant +4 weeks	2.40 $\pm$ 0.98*†	40.11 $\pm$ 4.12	2.88 $\pm$ 0.93	23.70 $\pm$ 1.45	37.29 $\pm$ 1.75*	21.26 $\pm$ 1.76

MR/LA% indicates mitral regurgitation jet area as a percentage of LA area; mitral annulus, septolateral measurement in long-axis view.

\*Significantly different from HF/all animals (baseline); †significantly different from HF/sham+4 weeks.

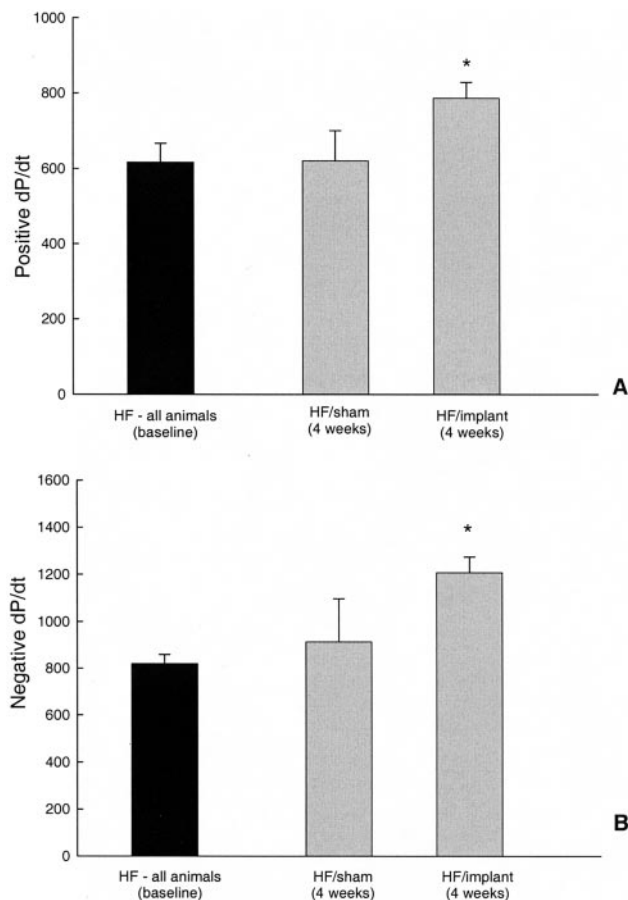


**Figure 2.** Hemodynamic data. A, Pulmonary artery wedge pressure. B, Cardiac output. Values are mean $\pm$ SEM. \*Significantly different ( $P<0.05$ ) from HF (baseline).

mals compared with HF baseline ( $P<0.05$ ). After 4 weeks of additional pacing, LA area was significantly increased in nonimplanted animals compared with both HF baseline animals and animals implanted with the PMAR device.

There was a significant ( $P<0.05$ ) decrease in pulmonary capillary wedge pressure (Figure 2A) in the HF/implant (4 weeks) group compared with HF baseline group, whereas cardiac output was not significantly (Figure 2B;  $P>0.05$ ) altered after chronic implantation of the device, although it tended to be higher than that in the untreated animals. Invasive indices of LV contractility (LV positive dP/dt; Figure 3A) and relaxation (LV negative dP/dt; Figure 3B), both determined from the derivative of LV pressure, were significantly increased in implanted animals at 4 weeks compared with HF baseline.

As a result of device implantation, there was a significant fall in plasma norepinephrine concentration (Figure 4A;  $P<0.05$ ) compared with that before implantation. In the present study, 4 weeks of added pacing led to a significant (Figure 4B;  $P<0.05$ ) increase in arterial BNP levels in the nonimplanted HF animals, whereas this significant increase was not observed ( $P>0.05$ ) in the animals implanted with the PMAR device. No atrial or ventricular arrhythmia occurred



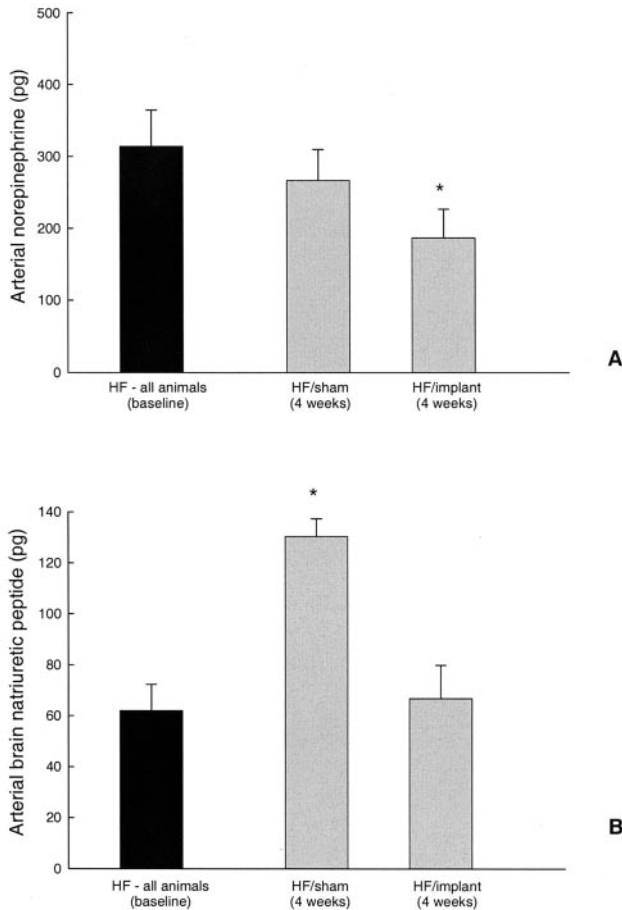
**Figure 3.** LV pressure derivatives. A, Positive dP/dt. B, Negative dP/dt. Values are mean $\pm$ SEM. \*Significantly different ( $P<0.05$ ) from HF (baseline).

during device placement. At postmortem analysis, examination of the hearts revealed no evidence of trauma or device displacement. In 5 animals implanted with the PMAR device, we performed venography of the coronary sinus just before they were killed. In all cases, the venous anatomy was normal, and no evidence of thrombus formation was apparent.

## Discussion

In this study we demonstrate for the first time that placement of a novel mitral annuloplasty device in the coronary sinus was found to effectively eliminate or diminish mitral regurgitation chronically in an ovine model of tachycardia-induced dilated cardiomyopathy. This finding extends a previous study by our group that investigated the acute effects of this device, in which we demonstrated an immediate hemodynamic benefit of device placement.<sup>15</sup> Chronic implantation of the device, despite the hemodynamic stress of continued pacing, led to a sustained hemodynamic and neurohormonal advantage, indicated by reduced wedge pressure and improved LV contractility. In addition, marked reductions in plasma norepinephrine and BNP correlated well with the observed functional response to PMAR.

The development of functional mitral regurgitation has been found to independently predict poorer survival in



**Figure 4.** Neurohormonal data. A, Arterial norepinephrine. B, Arterial BNP. Values are mean  $\pm$  SEM. \*Significantly different ( $P < 0.05$ ) from HF (baseline).

patients with HF and is clearly accompanied by increased exercise intolerance.<sup>20</sup> Although surgical approaches to the correction of HF-induced mitral regurgitation have been advocated, one of the key issues has related to the timing of surgery.<sup>21</sup> To a large degree, the difficulty in the timing or suitability for surgery relates to the difficulties associated with the assessment of LV contractile function in patients with mitral regurgitation. It is well recognized that the use of traditional ejection phase indices (such as ejection fraction) become even less reliable as measures of contractility because of the influence of mitral regurgitation on ventricular afterload.<sup>22,23</sup> In this context, restoration of valvular competency does not necessarily improve ejection fraction because of the resultant decrease in preload and increase in afterload.<sup>24,25</sup> Of interest, this phenomenon was observed in our study, as reflected by the minimal impact of PMAR implantation on LV ejection fraction. In control animals, ejection fraction fell slightly with further pacing, and this was accompanied by a tendency toward increasing mitral regurgitation. In our study we further assessed LV performance by invasive hemodynamic measurements. Using this approach, we showed that device placement improved both LV contractility and relaxation. This observation is supported by a previous study in which contractility was found to improve after mitral valve repair in a canine model of mitral regurgitation.<sup>26</sup>

Enhanced neurohormonal activation, including the sympathetic nervous system,<sup>4,5,27</sup> is known to play a key role in the pathophysiology of HF.<sup>28</sup> In association, marked elevations of plasma BNP are well documented in HF,<sup>29,30</sup> as measures of both ventricular dysfunction and prognosis. In this study the reduction in mitral regurgitation led to an improved neurohormonal profile with respect to both BNP and the adrenergic nervous system.

Our study also provides a new and interesting insight into the role of mitral regurgitation in the development of LA dilatation in the tachycardia-induced model of HF. It could be hypothesized that the dilatation of the LA commonly seen in this model is multifactorial, involving elevated LA pressures, atrioventricular dyssynchrony, and the effects of mitral regurgitation.<sup>31</sup> However, once mitral regurgitation had been eliminated, there was no further increase in LA area in the animals implanted with the PMAR device. Ventricular remodeling<sup>9,11</sup> and mitral annular dilatation<sup>10</sup> underpin the development of functional mitral regurgitation.

In the present study we showed that device placement reduced septolateral dimension and was associated with reduced mitral regurgitation. Our device does not necessarily alter the geometry of the anterior part of the annulus, which may also be of some relevance, as suggested by Hueb and colleagues.<sup>32</sup> The presence of mitral regurgitation results in exacerbation of cardiac remodeling, leading to further dilatation and increasing severity of mitral regurgitation, whereby "mitral regurgitation begets mitral regurgitation." Accordingly, the use of PMAR during the early stages of mitral regurgitation development may prevent this sequence and as a result may slow HF progression. In addition, by limiting the subsequent detrimental neurohormonal activation associated with mitral regurgitation, downstream cellular and molecular remodeling may also be reduced.

During this study the PMAR device was evaluated under harsh hemodynamic conditions whereby animals were continually paced throughout the protocol; however, it should be recognized that this study was performed in an ovine model, and efficacy has yet to be shown in a patient setting. Further studies are required to evaluate the efficacy of PMAR in mitral regurgitation in humans and to evaluate its impact on both quality of life and prognosis.

## Disclosure

D.M. Kaye, C.A. Alferness, and J.M. Power are founding stockholders in Cardiac Dimensions Inc. M. Byrne and D.G. Reuter are minor stockholders. D.M. Kaye is supported by the Atherosclerosis Research Trust.

## References

- Blondheim DS, Jacobs LE, Kotler MN, Costacurta GA, Parry WR. Dilated cardiomyopathy with mitral regurgitation: decreased survival despite a low frequency of left ventricular thrombus. *Am Heart J.* 1991; 122:763–771.
- Robbins JD, Maniar PB, Cotts W, Parker MA, Bonow RO, Gheorghiadu M. Prevalence and severity of mitral regurgitation in chronic systolic heart failure. *Am J Cardiol.* 2003;91:360–362.
- Junker A, Thayssen P, Nielsen B, Andersen PE. The hemodynamic and prognostic significance of echo-Doppler-proven mitral regurgitation in patients with dilated cardiomyopathy. *Cardiology.* 1993;83:14–20.
- Nagatsu M, Zile MR, Tsutsui H, Schmid PG, DeFreyte G, Cooper GT, Carabello BA. Native beta-adrenergic support for left ventricular dys-

- function in experimental mitral regurgitation normalizes indexes of pump and contractile function. *Circulation*. 1994;89:818–826.
5. Mehta RH, Supiano MA, Oral H, Grossman PM, Petruska JA, Montgomery DG, Briesmiester KA, Smith MJ, Starling MR. Relation of systemic sympathetic nervous system activation to echocardiographic left ventricular size and performance and its implications in patients with mitral regurgitation. *Am J Cardiol*. 2000;86:1193–1197.
  6. Oral H, Sivasubramanian N, Dyke DB, Mehta RH, Grossman PM, Briesmiester K, Fay WP, Pagani FD, Bolling SF, Mann DL, Starling MR. Myocardial proinflammatory cytokine expression and left ventricular remodeling in patients with chronic mitral regurgitation. *Circulation*. 2003;107:831–837.
  7. Masson S, Gorini M, Salio M, Lucci D, Latini R, Maggioni AP, for the IN-CHF Investigators. Clinical correlates of elevated plasma natriuretic peptides and big endothelin-1 in a population of ambulatory patients with heart failure: a substudy of the Italian Network on Congestive Heart Failure (IN-CHF) registry. *Ital Heart J*. 2000;1:282–288.
  8. Kaye DM, Jennings GL, Dart AM, Esler MD. Differential effect of acute baroreceptor unloading on cardiac and systemic sympathetic tone in congestive heart failure. *J Am Coll Cardiol*. 1998;31:583–587.
  9. Otsuji Y, Handschumacher MD, Schwammenthal E, Jiang L, Song JK, Guerrero JL, Vlahakes GJ, Levine RA. Insights from three-dimensional echocardiography into the mechanism of functional mitral regurgitation: direct in vivo demonstration of altered leaflet tethering geometry. *Circulation*. 1997;96:1999–2008.
  10. Timek TA, Dagum P, Lai DT, Liang D, Daughters GT, Ingels NB Jr, Miller DC. Pathogenesis of mitral regurgitation in tachycardia-induced cardiomyopathy. *Circulation*. 2001;104:147–153.
  11. Kono T, Sabbah HN, Rosman H, Alam M, Jafri S, Goldstein S. Left ventricular shape is the primary determinant of functional mitral regurgitation in heart failure. *J Am Coll Cardiol*. 1992;20:1594–1598.
  12. Nemoto S, Hamawaki M, De Freitas G, Carabello BA. Differential effects of the angiotensin-converting enzyme inhibitor lisinopril versus the beta-adrenergic receptor blocker atenolol on hemodynamics and left ventricular contractile function in experimental mitral regurgitation. *J Am Coll Cardiol*. 2002;40:149–154.
  13. Varriale P, David W, Chrysos BE. Hemodynamic response to intravenous enalaprilat in patients with severe congestive heart failure and mitral regurgitation. *Clin Cardiol*. 1993;16:235–238.
  14. Byrne MJ, Raman JS, Alferness CA, Esler MD, Kaye DM, Power JM. An ovine model of tachycardia-induced degenerative dilated cardiomyopathy and heart failure with prolonged onset. *J Card Fail*. 2002;8:108–115.
  15. Kaye DM, Byrne M, Alferness C, Power J. Feasibility and short-term efficacy of percutaneous mitral annular reduction for the therapy of heart failure-induced mitral regurgitation. *Circulation*. 2003;108:1795–1797.
  16. Eisenhofer G, Goldstein DS, Stull R, Keiser HR, Sunderland T, Murphy DL, Kopin IJ. Simultaneous liquid-chromatographic determination of 3,4-dihydroxyphenylglycol, catecholamines, and 3,4-dihydroxyphenylalanine in plasma, and their responses to inhibition of monoamine oxidase. *Clin Chem*. 1986;32:2030–2033.
  17. Medvedev OS, Esler MD, Angus JA, Cox HS, Eisenhofer G. Simultaneous determination of plasma noradrenaline and adrenaline kinetics: responses to nitroprusside-induced hypotension and 2-deoxyglucose-induced glucopenia in the rabbit. *Naunyn Schmiedeberg Arch Pharmacol*. 1990;341:192–199.
  18. Pemberton CJ, Yandle TG, Charles CJ, Rademaker MT, Aitken GD, Espiner EA. Ovine brain natriuretic peptide in cardiac tissues and plasma: effects of cardiac hypertrophy and heart failure on tissue concentration and molecular forms. *J Endocrinol*. 1997;155:541–550.
  19. Rademaker MT, Cameron VA, Charles CJ, Espiner EA, Nicholls MG, Pemberton CJ, Richards AM. Neurohormones in an ovine model of compensated postinfarction left ventricular dysfunction. *Am J Physiol*. 2000;278:H731–H740.
  20. Lamas GA, Mitchell GF, Flaker GC, Smith SC Jr, Gersh BJ, Basta L, Moye L, Braunwald E, Pfeffer MA, for the Survival and Ventricular Enlargement Investigators. Clinical significance of mitral regurgitation after acute myocardial infarction. *Circulation*. 1997;96:827–833.
  21. Otto CM. Timing of surgery in mitral regurgitation. *Heart*. 2003;89:100–105.
  22. Urschel CW, Covell JW, Sonnenblick EH, Ross J Jr, Braunwald E. Myocardial mechanics in aortic and mitral valvular regurgitation: the concept of instantaneous impedance as a determinant of the performance of the intact heart. *J Clin Invest*. 1968;47:867–883.
  23. Wisenbaugh T, Spann JF, Carabello BA. Differences in myocardial performance and load between patients with similar amounts of chronic aortic versus chronic mitral regurgitation. *J Am Coll Cardiol*. 1984;3:916–923.
  24. Wong CY, Spotnitz HM. Systolic and diastolic properties of the human left ventricle during valve replacement for chronic mitral regurgitation. *Am J Cardiol*. 1981;47:40–50.
  25. Schuler G, Peterson KL, Johnson A, Francis G, Dennish G, Utley J, Daily PO, Ashburn W, Ross J Jr. Temporal response of left ventricular performance to mitral valve surgery. *Circulation*. 1979;59:1218–1231.
  26. Nakano K, Swindle MM, Spinale F, Ishihara K, Kanazawa S, Smith A, Biederman RW, Clamp L, Hamada Y, Zile MR, et al. Depressed contractile function due to canine mitral regurgitation improves after correction of the volume overload. *J Clin Invest*. 1991;87:2077–2086.
  27. Tsutsui H, Spinale FG, Nagatsu M, Schmid PG, Ishihara K, DeFreyte G, Cooper Gt, Carabello BA. Effects of chronic beta-adrenergic blockade on the left ventricular and cardiocyte abnormalities of chronic canine mitral regurgitation. *J Clin Invest*. 1994;93:2639–2648.
  28. Kaye DM, Lefkovits J, Jennings GL, Bergin P, Broughton A, Esler MD. Adverse consequences of high sympathetic nervous activity in the failing human heart. *J Am Coll Cardiol*. 1995;26:1257–1263.
  29. Mukoyama M, Nakao K, Hosoda K, Suga S, Saito Y, Ogawa Y, Shirakami G, Jougasaki M, Obata K, Yasue H, et al. Brain natriuretic peptide as a novel cardiac hormone in humans: evidence for an exquisite dual natriuretic peptide system, atrial natriuretic peptide and brain natriuretic peptide. *J Clin Invest*. 1991;87:1402–1412.
  30. Maisel AS, Krishnaswamy P, Nowak RM, McCord J, Hollander JE, Duc P, Omland T, Storrow AB, Abraham WT, Wu AH, Clopton P, Steg PG, Westheim A, Knudsen CW, Perez A, Kazanegra R, Herrmann HC, McCullough PA. Rapid measurement of B-type natriuretic peptide in the emergency diagnosis of heart failure. *N Engl J Med*. 2002;347:161–167.
  31. Tsang TS, Barnes ME, Gersh BJ, Bailey KR, Seward JB. Left atrial volume as a morphophysiologic expression of left ventricular diastolic dysfunction and relation to cardiovascular risk burden. *Am J Cardiol*. 2002;90:1284–1289.
  32. Hueb AC, Jatene FB, Moreira LF, Pomerantzeff PM, Kallas E, de Oliveira SA. Ventricular remodeling and mitral valve modifications in dilated cardiomyopathy: new insights from anatomic study. *J Thorac Cardiovasc Surg*. 2002;124:1216–1224.